

Symptoms Detection in Eye Retina Image

Daniel Košťalik

Brno University of Technology
Faculty of Information Technology
Centre of Excellence IT4Innovations
Czech, Brno

Lukáš Maruniak

Brno University of Technology,
Faculty of Information Technology
Centre of Excellence IT4Innovations
Czech, Brno

Martin Drahanský, Senior IEEE Member

Brno University of Technology
Faculty of Information Technology
Centre of Excellence IT4Innovations
Czech, Brno

Abstract—Diabetic retinopathy and age related macular degeneration are among the most common eye retina diseases [1], which cause partial or complete blindness. The purpose of this thesis is to design and implement software for automatic detection of symptoms from eye fundus images. The detection algorithm is based on segmentation methods and afterwards analysis. Determination of retina objects such as optic disc, macula and blood vessels is important prior symptoms detection as they can adversely affect the results of the analysis. Total 259 images of four databases were analyzed and algorithm reaches more than 90 % average success rate. The software may be useful in combination with appropriate hardware and optic mechanism, which forms one of practical application in global population screening.

I. INTRODUCTION

Sense of sight is considered as the most important sense, which enables people gaining most of information from the ambient environment. Vision loss or its worsening has a significant impact on the quality of life. Just a little disruption of any part of eye can result in total blindness. Human brain and eyes are equal partners in vision processing. Their connection is mediated by the retina, which consists of light sensitive cells: rods and cones, which produce electric impulses and send them via optic nerves to the brain. Thus the retina is the most important and sensitive part of the human eye. Retinal disorders can affect vision and some of them might be serious enough to cause blindness. One of the most common retinal disorders is diabetic retinopathy. Approximately 2,6 % [3] complete blindness is caused by diabetes. Because of the steep rising curve of patients suffered by diabetes, it is medical-social challenge to strive with this disease. Another the most common disorder which causes complete blindness of retiree (60 years+) is aged related macular degeneration. The tremendous progress of computer technology in the past 20 years has brought image processing to many scientific fields. There have been several algorithms and approaches developed how to use image processing techniques in order to automatically detect symptoms of retinal diseases. The main goal of this thesis is to design alternative algorithm how to detect symptoms of diabetic retinopathy and age related macular degeneration. Retinal diseases are distinctive by gradual progress and in many cases patients do not realize that they suffer from any illness. Through global screening, ophthalmologists can commence with suitable medical therapy

and avoid further disease progress and in many cases save patient's eyesight.

II. DETERMINATION OF RETINAL OBJECTS

A. Region of interest (ROI) masking

Region of interest (ROI) masking Fundus camera output is a image of a retinal part with circle shape. The capture with black background makes the final image. Further processing requires the necessity of separation of the region of interest and background. For this purpose it is possible to use complementary binary matrix, which values determine the area of retina (value 1) and background (value 0). Thanks to elimination of background in pre-processing, algorithm for symptom detection speeds up. An elementary operation – thresholding is used to make ROI mask. Because of a noise contained in background, first of all it is necessary to blur image using the normalized box filter with grid size 5×5 .

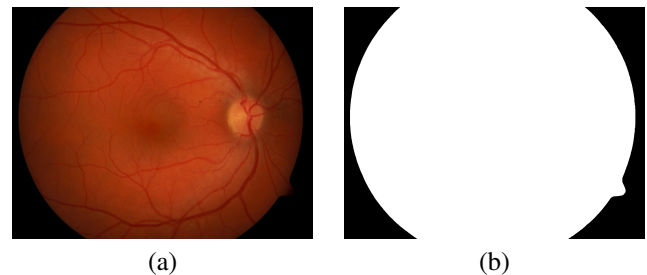


Fig. 1: Fundus image and ROI - region of interest.

B. Optic disc

Optic disc is a part of retina, where central retinal artery and nerve fiber enter to retina. This object is orange/yellow circle with 1,5 mm diameter [4]. The reason why it is necessary to determinate optic disc, that optic disc, in many case, is similar as symptoms, especially as hard exudates and automatic detection detects optic disc as exudate. In general, there are a lots of approaches, which deal with detection of optic disc. Some of them are based on detection by the highest intensity area in image. This approach works well with images, with no symptoms. Symptoms such as hard exudates have similar intensity value as optic disc, so algorithm could bring wrong results. In order to improve algorithm it is suitable

to find location of the optic disc. Thanks to a physiology of human eye it is possible to estimate position of optic disc in fundus image. Position is affected by variability of eyes, type of eye (left-right), position of head and eye according to fundus camera lens in process of making retinal snapshots. Further improvement can be carried out by gradually thresholding. Before thresholding it is necessary to pre-process retinal image. By splitting RGB channels we reached three images. There on the green channel image contrast limited adaptive histogram equalization is applied. Thanks to this operations a better recognition of single parts of retina is achieved as we can see in Fig. 4 (d). There on the pre-processed image gradually thresholding with start threshold value 255 is applied. After every iteration, the threshold value is decreased and resulted areas are analysed. Number of pixels is counted for each gained area. In case that some of these areas reaches number of pixels equal or greater than 450, algorithm stops, and this area is considered as optic disc.

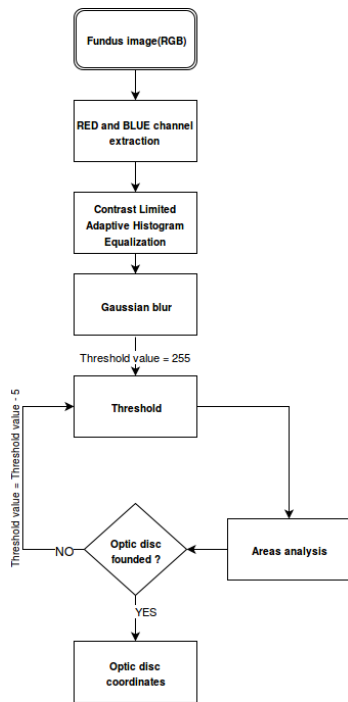


Fig. 2: Optic disc detection algorithm.

C. Fovea

Fovea is a part of retina, which is the most sensitive, because it contains the most rods and cones, which provides human vision. Fovea is little bit darker than retinal background and algorithm for detection of symptoms in some cases could lead to the wrong detected fovea as symptom - especially hemorrhage. By determination of fovea it is possible to eliminate incorrect detection. Finding the fovea position it is also possible to use it for classification and relevance of disease. Symptoms placed in this area have the highest impact to quality of sight. Centre of fovea is relatively placed with respect to optic nerve head.

The distance between the optic nerve head and the fovea does not allow for a meaningful determination of the location of the fovea in eyes in which morphologic changes have occurred [5]. Another factor is diversity of macula through population [12]. There in Fig. 3 all fovea centres are represented relatively to optic disc from databases Diaretdb0. Radius for suspicious was set to 80 pixels according to experiments with database. In this area is applied algorithm gradually thresholding the same way as it was used for optic disc, but algorithm starts with threshold value 0 and every iteration threshold value increments. If some of gained area reached 50 pixels, algorithm stops and this area is considered as fovea.




Fig. 3: Relative positions of foveas centers to optic disc.

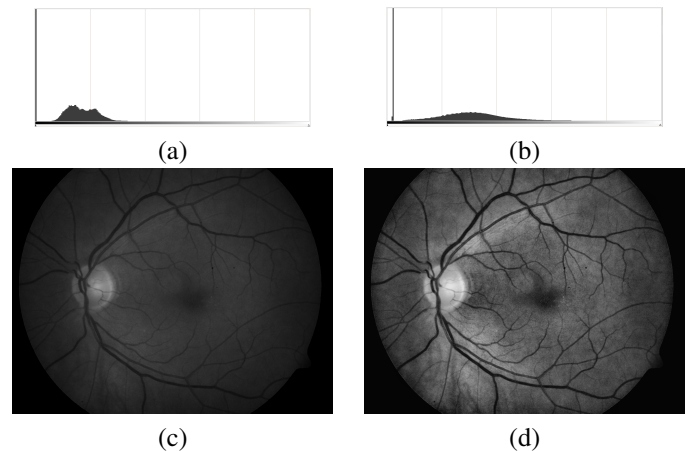


Fig. 4: Original histogram (a), Equalized histogram (b), Original green channel fundus image (c), Contrast limited adaptive histogram equalization (d).

D. Blood vessels determination

In fundus images we can observe blood vessels (veins and arteries), which are very important for retina, because it nourish function. Thanks to determination of blood vessels, it is possible to reach much better results for symptoms detection. Retinal vessels uniqueness is possible to use for detection in biometry area. If algorithm processes images with no determined vessels, algorithm slows down and uselessly

process vessels areas, which may even cause wrong detection. To highlight vessels, the contrast limited adaptive histogram equalization to green channel of fundus image is used. This improvement we can observe in Fig. 4 (b). Adaptive Gaussian [13] threshold which caused that vessels create continuous areas is applied on this image. Background of retina is covered by noise, which might be reduced by morphological opening, which is based on operation erosion (1) followed by a dilation (2).

$$M \ominus B = \{p \in E^2 : p + B \in A, \forall b \in B\} [16] \quad (1)$$

$$M \oplus B = \{p \in E^2 : p = m + b, m \in M, B \in B\} [16] \quad (2)$$

Finally growing region algorithm [8], which analyses all areas, is applied to image and the areas which are too small to be vessels are extracted. This is necessary because image with vessels still contains background, symptoms or optic disc remains. There in Fig. 4 (f) we can observe that dividing line between retina and background is also detected as vessel. This is a wrong detection, but in further processing it does not influence on correctness of symptoms detection.

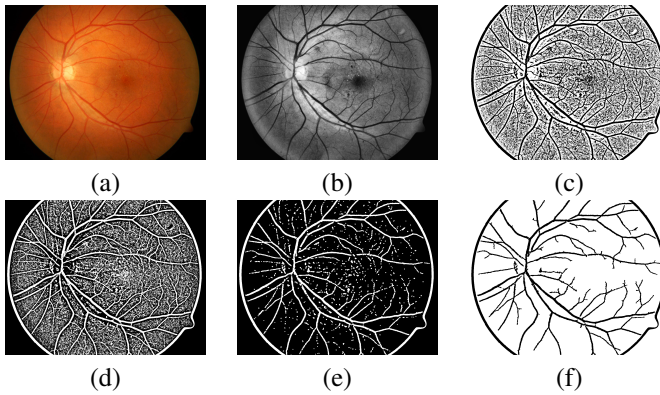


Fig. 5: Original fundus image (a), Green channel image with equalized histogram (b), Adaptive Gaussian threshold (c), Inverted image (d), morphology operation - open (e), Small areas determination (f).

III. DETECTION OF EXUDATES AND DRUSENS

Hard (Fig. 6) and soft exudates belong to the prior features of diabetic retinopathy. These symptoms are largely made up of lipid which has leaked from abnormal retinal capillaries. Drusen (Fig. 7) are also made up of lipids and are hallmark of age-related macular degeneration [9] [10]. A lot of factors such as density of extravascular space, density of lipids, permeability, blood vessels damage rate and others, have impact on size, shape and colour of them. Algorithm for detection does not distinguish these symptoms and detect both as one. Symptoms as exudates and drusen stymie retinal rods and cons to process light beams passing through lens, which results in that brain gets less optical information and final image absent visual information and is damaged.

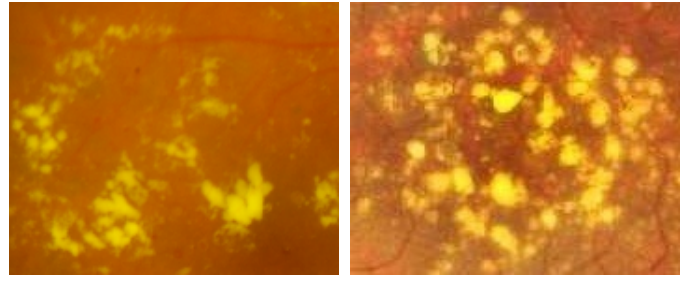


Fig. 6: Exudates.

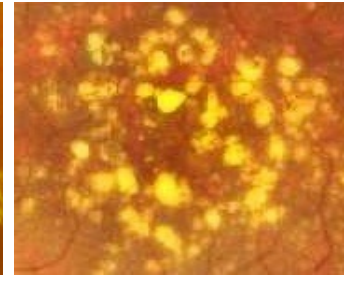


Fig. 7: Drusen.

Algorithm for detection uses pre-processing operations described above (region of interest detection, blood vessels and optic disc determination). The first operation applied to input image is detection of ROI following by linear image processing operation - blurring to gray-scaled image. Blurring eliminates noise and speeds up further processing. Normalized matrix with matrix 5×5 is used to blur image. The core of method for exudate and drusen detection is growing region algorithm. Growing region segments image to the uniform homogenate regions. Intensity of new made region is calculated as average of all pixel intensities included in new area. The homogenate value is set to 8. Adjacent pixels with intensities difference less than 8 from given intensity are added to new region. All gained areas are analysed and areas containing more than 4,000 pixels are extracted. These areas are too big to be exudate or drusen.

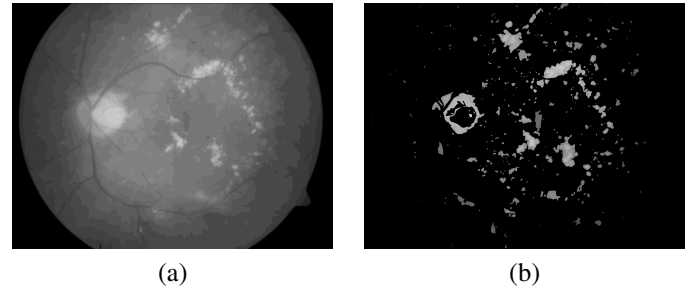


Fig. 8: Segmented regions by region growing algorithm (a), Suspicious areas get from segmented image (b).

Detection of symptoms is based on finding, that areas which represent exudate and drusen create contour lines. Intensity of contour lines is more and lighter radially out of the centre of area as we can observe in Fig. 9 (b). Contour lines are detected by peaks of areas. Every peak intensity value is compared with adjacent pixel out of area and if all (top, right, bottom, left) peaks adjacent pixels are smaller, than this area is considered as contour line. In order to increase accuracy it is possible to check how many layers are overlapping. Algorithm checks not only adjacent pixel, but also next 50 pixels lying straight out of area. Wrong detection could be caused by areas between vessels which also make contour lines. To reduce wrong detection it is possible to use blood vessels detection and morphology operation - dilation. Vessels dilation causes,




Fig. 9: Hard exudate (a), Contour lines (b), Contour lines - detail (c), Marked exudates (d).

that small areas between vessels merge and space for contour lines is eliminated. The correctness of detection is also influenced by Panretinal photocoagulation [11]. Laser treatment causes photocoagulation spots, which are quite similar to soft exudates. According to started treatment it is not necessary to distinguish spots and exudates or drusen.

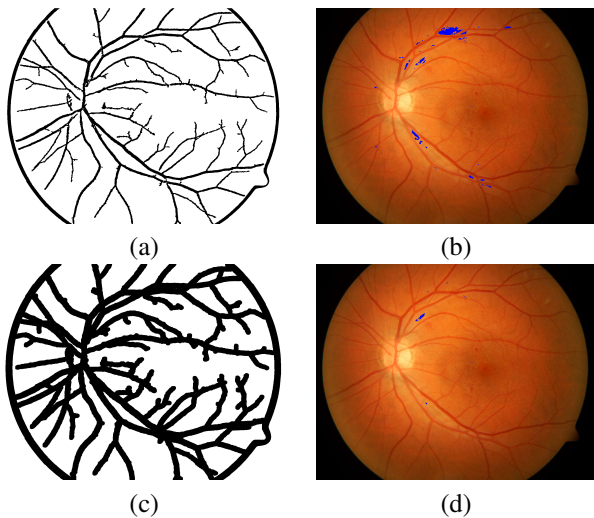


Fig. 10: Blood vessels (a), Wrong detection (b), Blood vessels - dilatation. (c), Eliminated wrong detection (d).

IV. DETECTION OF MICROANEURYSM AND HEMORAGIES

Microaneurysms are small circular deep-red dots in the fundus and size ranges from $14 \mu\text{m}$ to $136 \mu\text{m}$. However they belong to typical diabetic retinopathy symptoms, they can not be considered as pathognomonic symptom. Sometimes

the microaneurysms rupture and blood spills into the retina to form dot hemorrhages. Algorithm for detection considers both symptoms as the one and is based on algorithm for exudates detection described above. At the first point it is necessary to pre-process image. Contrast limited adaptive histogram equalization is applied to image, which causes highlighting of small red dots - microaneurysm and hemorrhages. Then Gaussian blur with kernel size 5×5 which speed up afterward growing region algorithm, is applied. While smoothing process it is necessary to be cautious with setting of matrix size. Too large matrix causes that small dots merge with background and on the other hand too small causes that algorithm image processing takes long time. Growing region segments image to homogeneous regions. Homogeneous value is set to 10. Detected areas with more than 5,000 pixels are removed, because these areas represent background and are too big to be symptom.




Fig. 11: Microaneurysms (a), Contour lines (b), Marked areas (c).

To detect microaneurysms and hemorrhages finding is used that areas which create contour lines represent symptoms. The same approach was used at exudates detection, but in this case contour lines become darker towards to center of symptom as we can observe in Fig. 11 (b).

V. EVALUATION AND DISCUSSION

Algorithm is in default designed for databases Diaretdb0 and Diaretdb1, which offers 219 fundus images in total with diabetic retinopathy symptoms. The algorithm was optimized and tested over these databases.

A. Ground truth

To evaluate algorithm it was necessary to compare results of automatic detection with real results evaluated by ophthalmologist. Because manual evaluation of fundus images is demanding human resources and is time consuming, ground truth database was created by student of medicine. To make creation of ground truth database more user friendly, application which offer to user easily mark symptoms was developed. Basic user interface you can see in Fig. 12. Left side of the image with automatic detected symptoms is covered by matrix. User can mark correctly automatic evaluated pixels (25×25). There is on the right side the original fundus image. Output of this application is structure with all information. Most important parameters are: true positive, true negative, false positive and false negative.

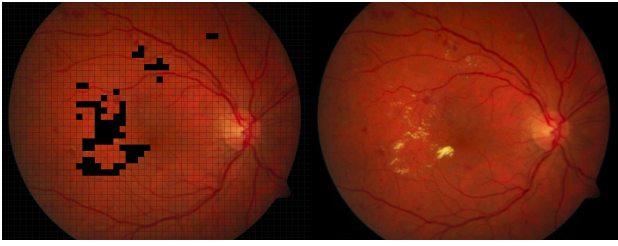


Fig. 12: Process of evaluation.

B. Results

It is good practice in medical research to evaluate results by using Sensitivity, Specificity and Precision. In this case sensitivity indicates, how well the algorithm detects symptoms. Specificity indicates how well algorithm does not detect healthy areas of retina. These parameters are computed as:

$$\text{Sensitivity} = \frac{TP}{TP + FN} \quad (3)$$

$$\text{Specificity} = \frac{TN}{TN + FP} \quad (4)$$

$$\text{Precision} = \frac{TP}{TP + FP} \quad (5)$$

1) *Diaret databases*: Results of detection optic disc and symptoms over databases Diaretdb0 and Diaretdb1 are represented in following tables:

Database	Right detected	Wrong detected	Accuracy
Diaretdb0	85	4	95.29 %
Diaretdb1	126	4	96.82 %

TABLE I: Results - Optic disc detection.

Diaretdb0	Sensitivity	Specificity	Precision
Exudates a drusen	94.26 %	99.41 %	99.65 %
Microaneurysm and hemorrhages	92.66 %	99.24 %	99.24 %

TABLE II: Results - Symptoms detection over Diaretdb0 database.

Diaretdb1	Sensitivity	Specificity	Precision
Exudates a drusen	90.28 %	99.32 %	99.65 %
Microaneurysm and hemorrhages	91.46 %	99.35 %	99.42 %

TABLE III: Results - Symptoms detection over Diaretdb1 database.

2) *Other databases*: To demonstrate possibility to use algorithm through other databases were used HRFIDB [15] and DRIVE [14] databases with 36 images.

Database	Right detected	Wrong detected	Accuracy
HRFIDB	16	0	100 %
DRIVE	19	1	94.73 %

TABLE IV: Results - Optic disc detection.

HRFIDB	Sensitivity	Specificity	Accuracy
Exudates and drusen	69.81 %	98.76 %	98.36 %
Microaneurysm and hemorrhages	18.3 %	99.87 %	99.51 %

TABLE V: Results - Symptoms detection over HRFIDB database.

Drive	Sensitivity	Specificity	Accuracy
Exudates and drusen	63.63 %	99.70 %	99.7 %
Microaneurysm and hemorrhages	NA%	98.63 %	98.53 %

TABLE VI: Results - Symptoms detection over DRIVE database.

VI. CONCLUSION

The main goal of this work was to design algorithm for symptoms detection in human eye fundus images. Algorithm is focused on two most common diseases: diabetich retinopathy and age related macular degeneration. Before symptoms detection it is necessary to remove parts of retina such as optic disc, fovea and blood vessels. These parts can adversely affect the result of the analysis. Detection approach is based on region growing algorithm and the most important research finding is that segmented regions form contour lines. Thanks to contour lines, algorithm can detect symptoms over 90 % precision. One of potential usage of algorithm could be implemented by composition with appropriate hardware and fundus camera. This system can be used in global screening without presence of ophthalmologist. Another possible utilization of algorithm offer identification and verification in biometrics systems. Thanks to the synergy connection it is possible to spread functionality of system and mainly detect symptoms in time, when it known methods can heal the disease.

ACKNOWLEDGMENT

This work was supported by The Ministry of Education, Youth and Sports from the National Programme of Sustainability (NPU II) project IT4Innovations excellence in science - LQ1602.

REFERENCES

- [1] Medically Reviewed by Alana Biggers, MD, MPH on August 4, 2016 — Written by Valencia Higuera, URL <http://www.healthline.com/health/macular-degeneration>
- [2] Sosna, T.: *Diabetická retinopatie*. Praha: Axonite CZ, second edition, 2016, ISBN 9788088046059
- [3] Bourne, R. R. A.; Stevens, G. A.; White, R. A.; aj.: Causes of vision loss worldwide, 1990–2010: a systematic analysis. *The Lancet Global Health*, volume 1, n. 6, 2013: p. 339–349, ISSN 2214-109X, doi:[https://doi.org/10.1016/S2214-109X\(13\)70113-X](https://doi.org/10.1016/S2214-109X(13)70113-X).
- [4] Vlková, E.; Šárka Pitrová; Vlk, F.: *Lexikon očního lékařství: výkladový ilustrovaný slovník*. Brno: František Vlk, 2008, ISBN 9788023989069.
- [5] Determination of the Location of the Fovea on the Fundus. 1997, [Online; navštíveno 11.04.2017]. URL <http://iovs.arvojournals.org/article.aspx?articleid=2163282>
- [6] Kauppi, T.; Kalesnykiene, V.; k. Kamarainen, J.; aj.: DIARETDB0 diabetic retinopathy database and evaluation protocol. 2006. URL <http://www.it.lut.fi/project/imageret/diaretdb0/>
- [7] Kauppi, T.; Kalesnykiene, V.; k. Kamarainen, J.; aj.: DIARETDB1 diabetic retinopathy database and evaluation protocol. 2007. URL <http://www.it.lut.fi/project/imageret/diaretdb1/>
- [8] Kamdi, S.; Krishna, R.: Image Segmentation and Region Growing Algorithm. *International Journal of Computer Technology and Electronics Engineering*, ročník 2, č. 18, 2012: s. 103–107, ISSN 2249 - 6343.
- [9] Ernest, J.: *Makulární degenerace*. Praha: Mladá fronta, první vydání, 2010, ISBN 9788020423634.
- [10] Kolář, P.: *Věkem podmíněná makulární degenerace*. Praha: Grada, první vydání, 2008, ISBN 9788024726052.
- [11] Jhawe, S.; Karth, W. P. A.: Panretinal Photocoagulation. Oct 2016, online; navštíveno 11.04.2017. URL http://eyewiki.aao.org/Panretinal_Photocoagulation
- [12] Li, X.; Wong, W.; Cheung, C.; aj.: Racial differences in retinal vessel geometric characteristics: a multiethnic study in healthy Asians. *Investigative Ophthalmology & Visual Science*, , č. 54, 2013: s. 3650–3656, doi:10.1167/iovs.12-11126
- [13] R.FISHER, A. W. E. W., S.Perkins: Gaussian distribution. 2000. URL <http://homepages.inf.ed.ac.uk/rbf/HIPR2/gsmooth.htm>
- [14] J.J. Staal, M.D. Abramoff, M. Niemeijer, M.A. Viergever, B. van Ginneken, "Ridge based vessel segmentation in color images of the retina", *IEEE Transactions on Medical Imaging*, 2004, vol. 23, pp. 501-509.
- [15] Köhler, T.; Budai, A.; Kraus, M.; aj.: Automatic No-Reference Quality Assessment for Automatic No-Reference Quality Assessment for Retinal Fundus Images Using Vessel Segmentation. *IEEE International Symposium on Computer-Based Medical Systems*, ročník 26, 2013.
- [16] Pavlovičová, J.: *Číslíkové spracovanie obrazu*. Fakulta elektrotechniky a informatiky, Slovenská technická univerzita, Bratislava, 2016, [Online; visited 11.04.2017]. URL <http://ibooks.sk/publ/12pavlovicova/>